

ARTO INFERIORE:

- anca
- coscia
- gamba
- piede

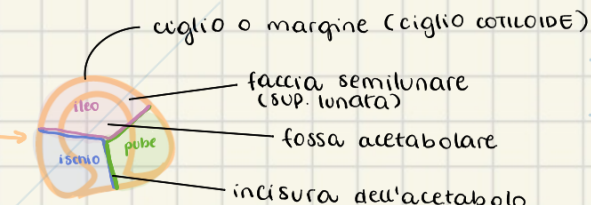
ANCA:

- cintura pelvica
- complesso della pelvi (insieme a osso sacro e cocige)
- 3 ossa fuse insieme:

- ileo
- ischio
- pube

→ punto di saldatura = **acetabolo**

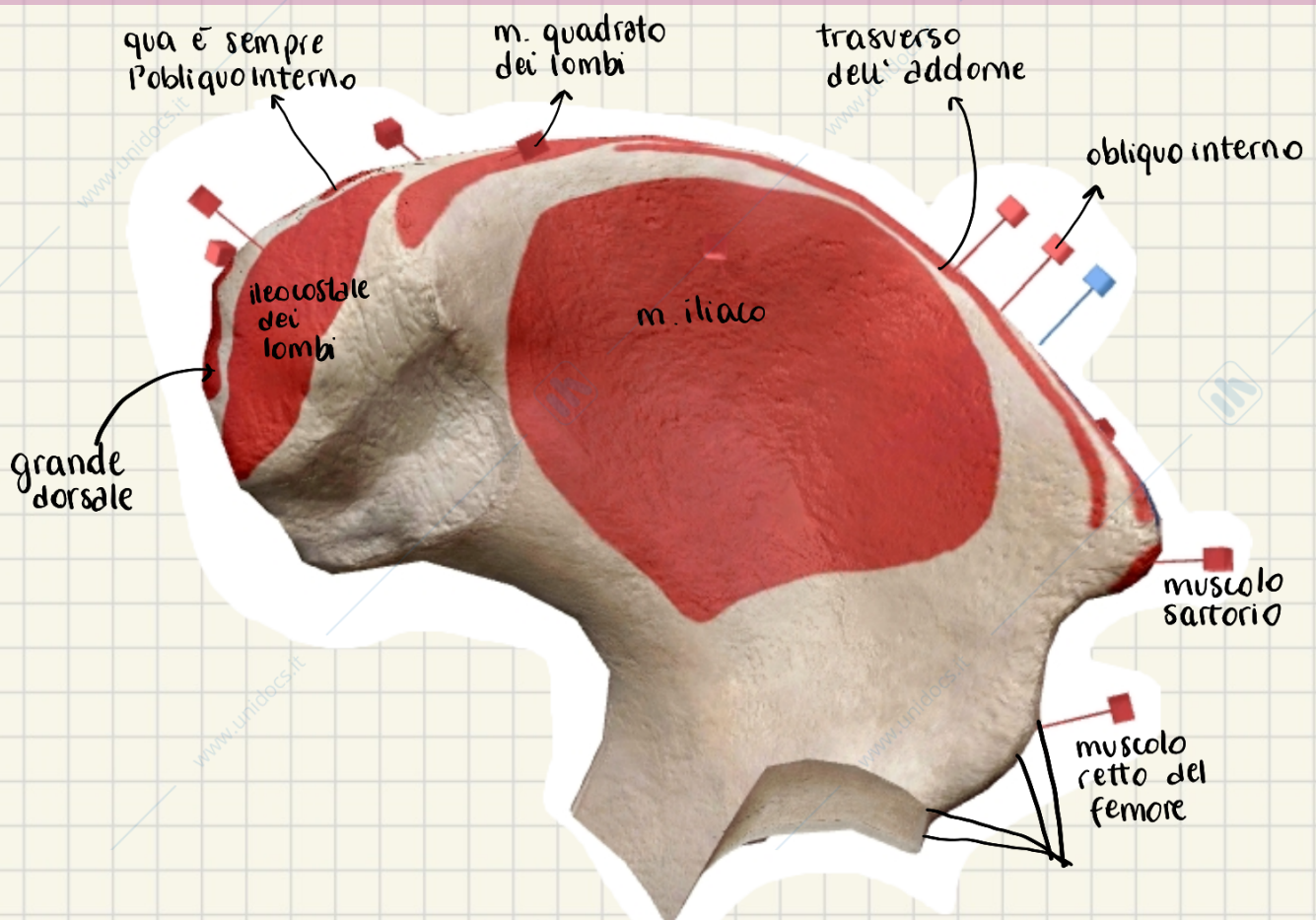
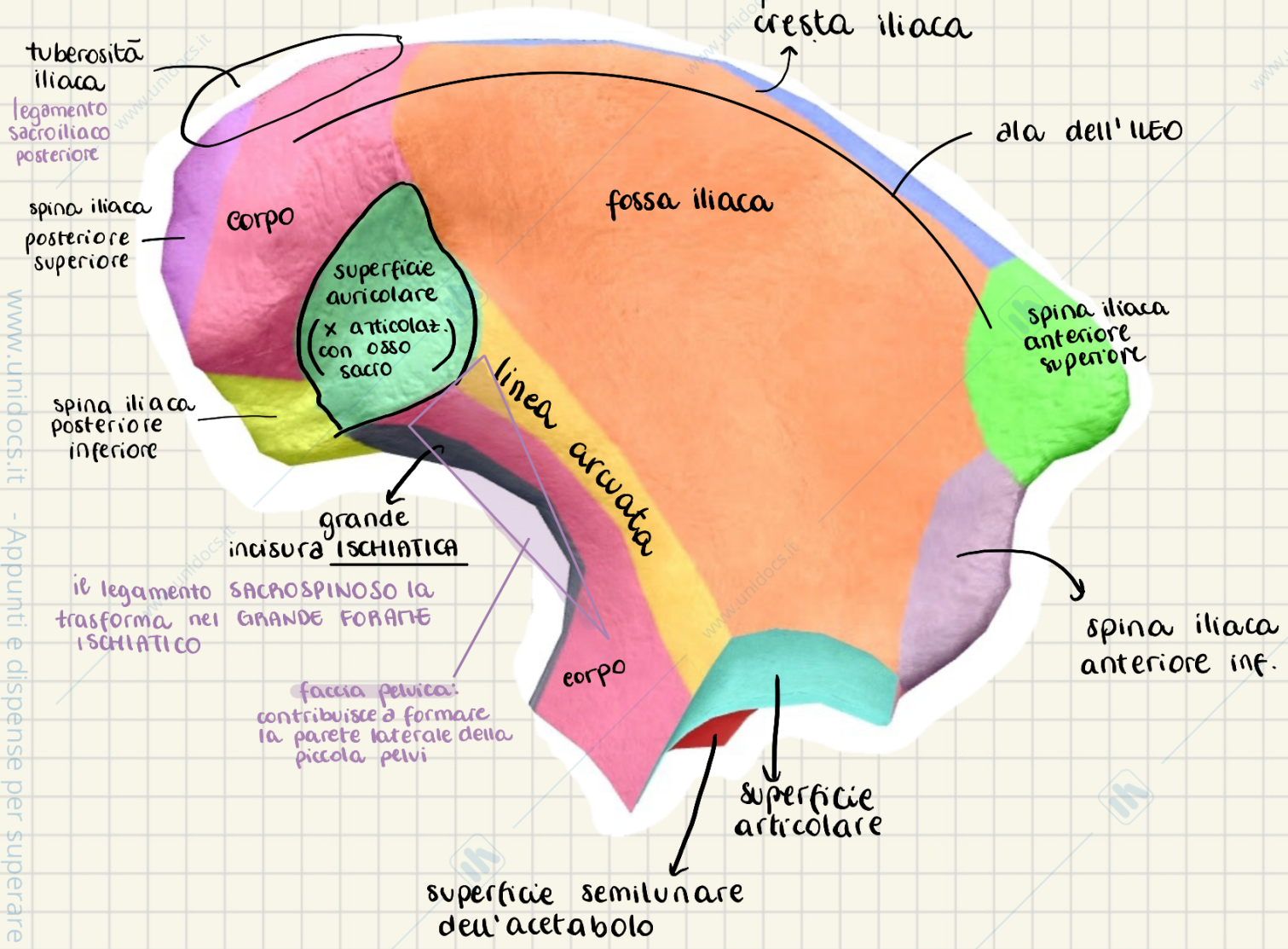
- cavità emisferica che accoglie testa del femore
- delimitata da **CIGLIO** o **MARGINE**
- unico punto di fusione evidente è quello tra **ISCHIO** e **PUBE**
- margine < solco **SOPRACETABOLARE** < ileo
- faccia semilunare = sup. art interrotta da incisura
- fossa dell'acetabolo = sup. rugosa non articolare



→ **forame otturato** sotto acetabolo

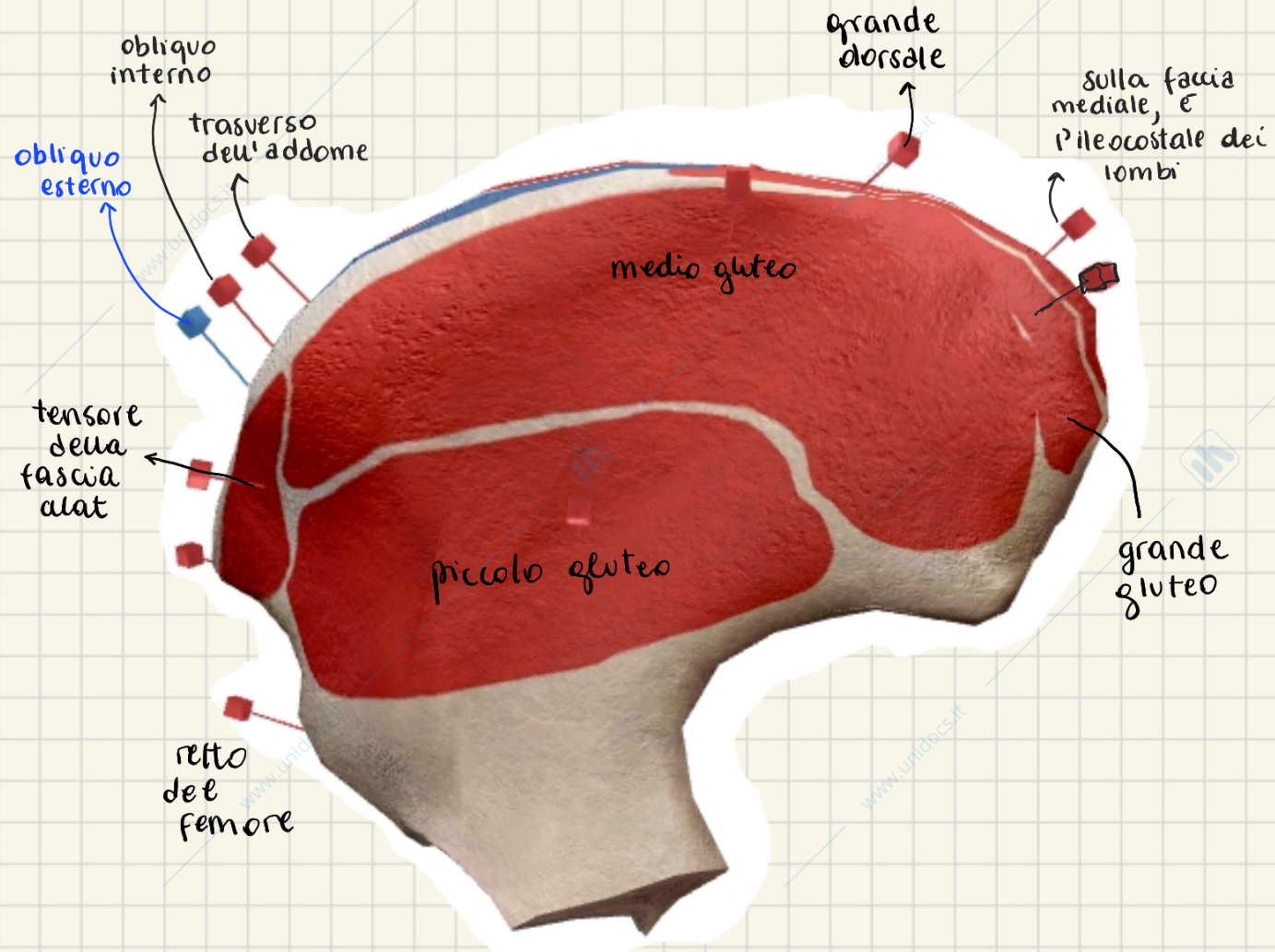
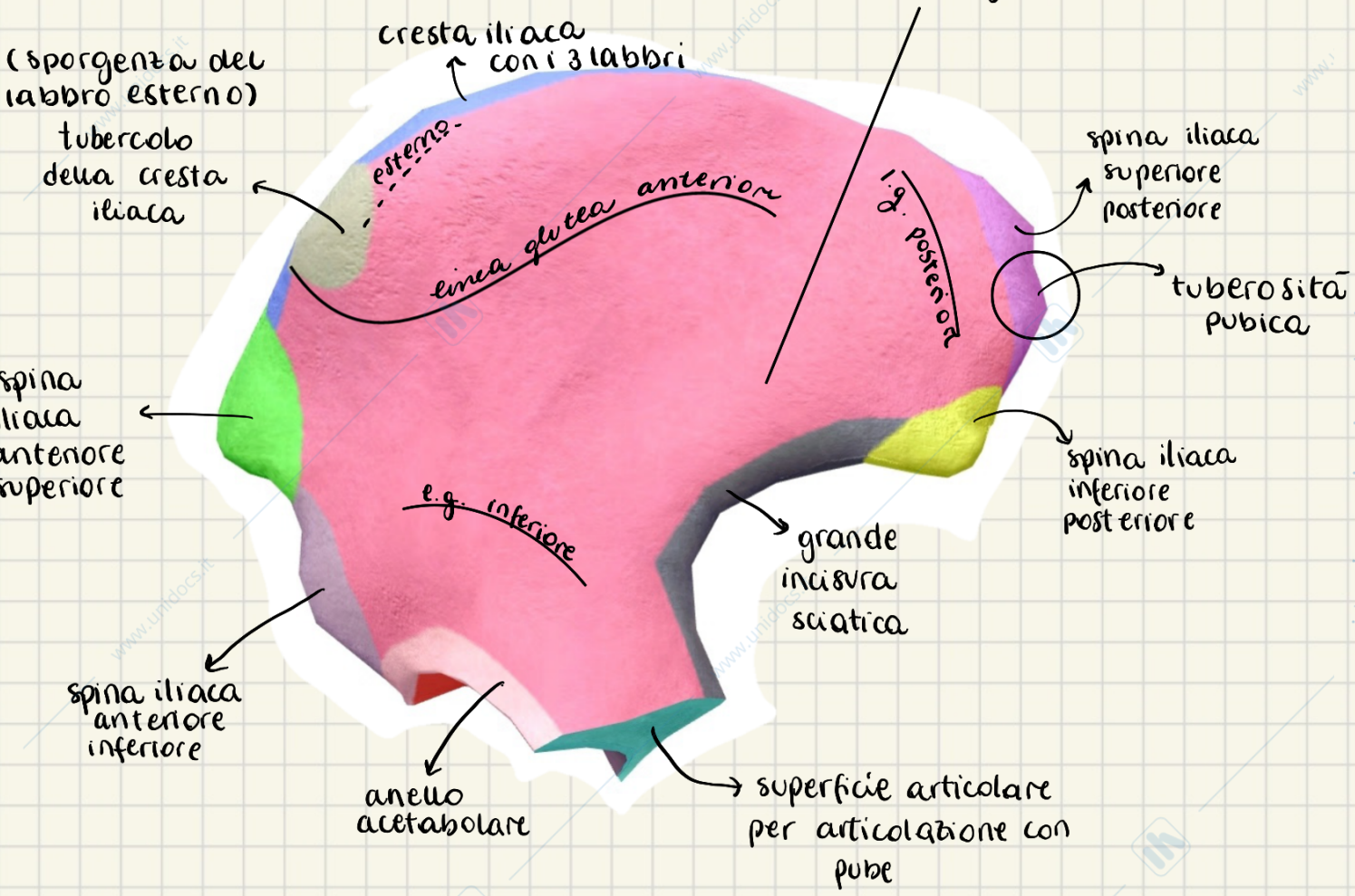
- ○ maschio
 - Δ femmina
- delimitato da:
 - S.A. pube
 - P.I. ischio
 - è otturato dalla **MEMBRANA OTTURATORIA**
 - S.A. abbiamo solco otturatorio → **CANALE OTTURATORIO**
passaggio x fascio vascolo-nervoso otturatorio

visione mediale = f. sacropelvica

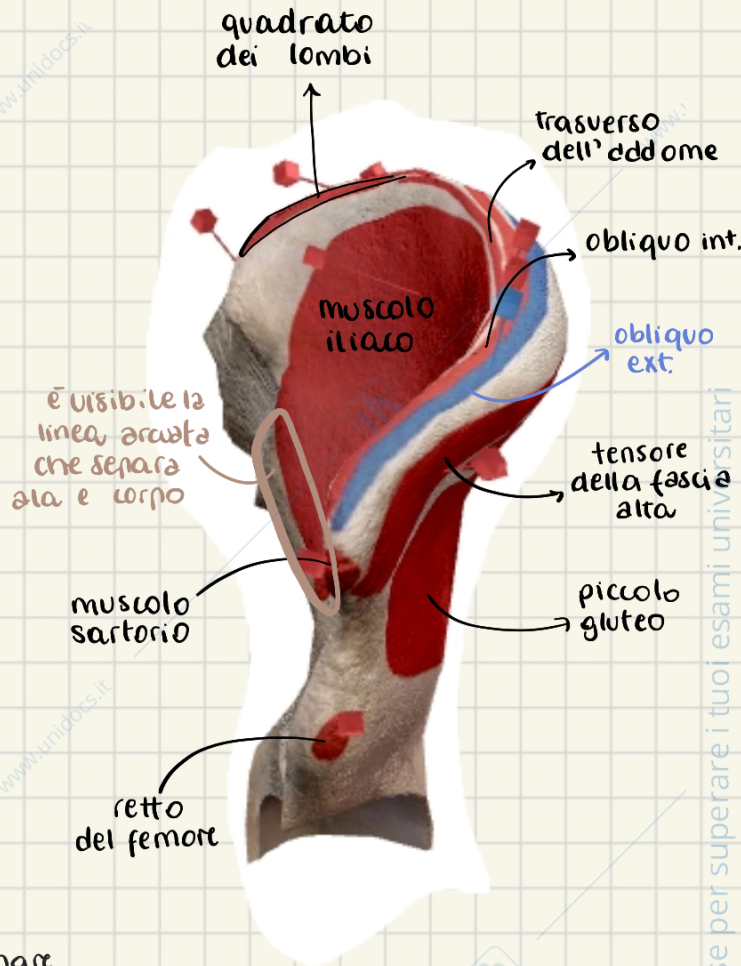
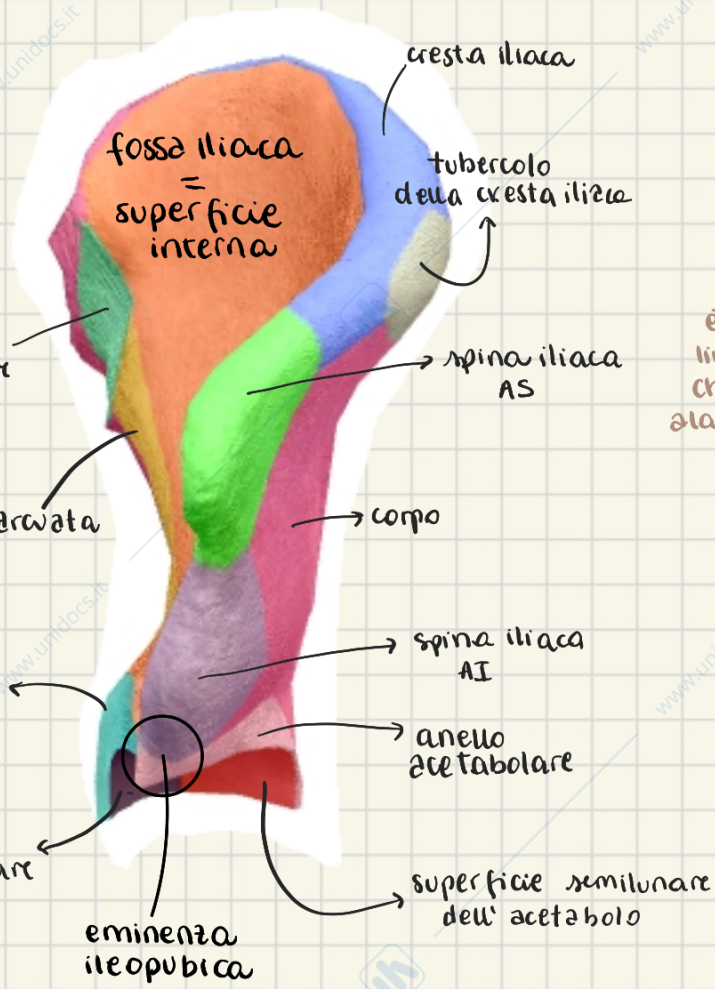


visione laterale = faccia glutea

corpo = faccia glutea

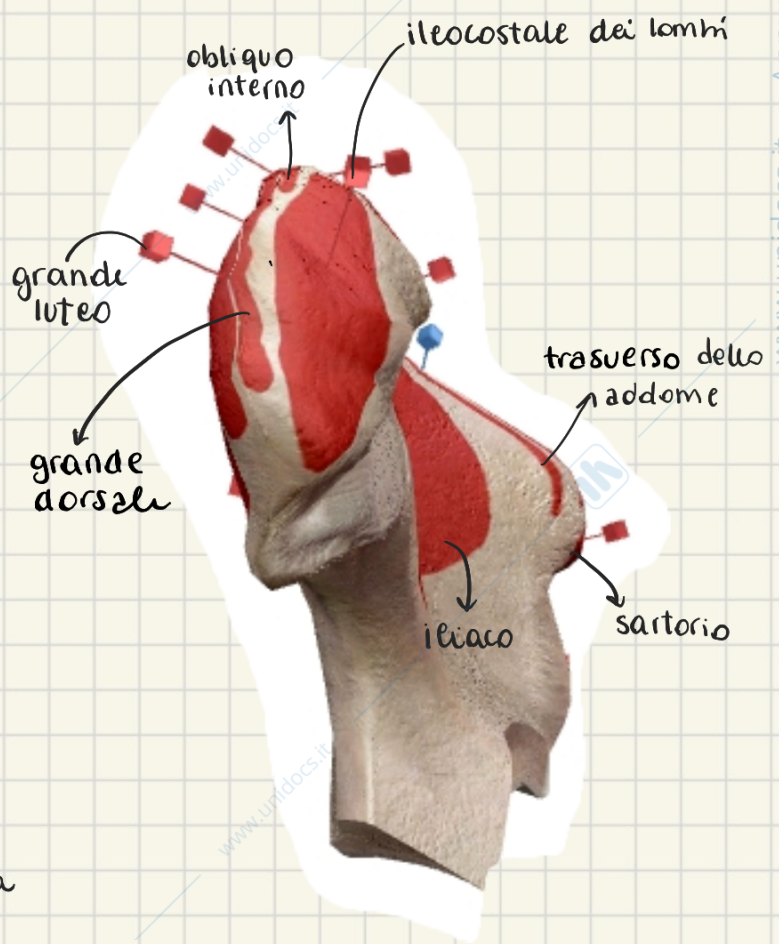
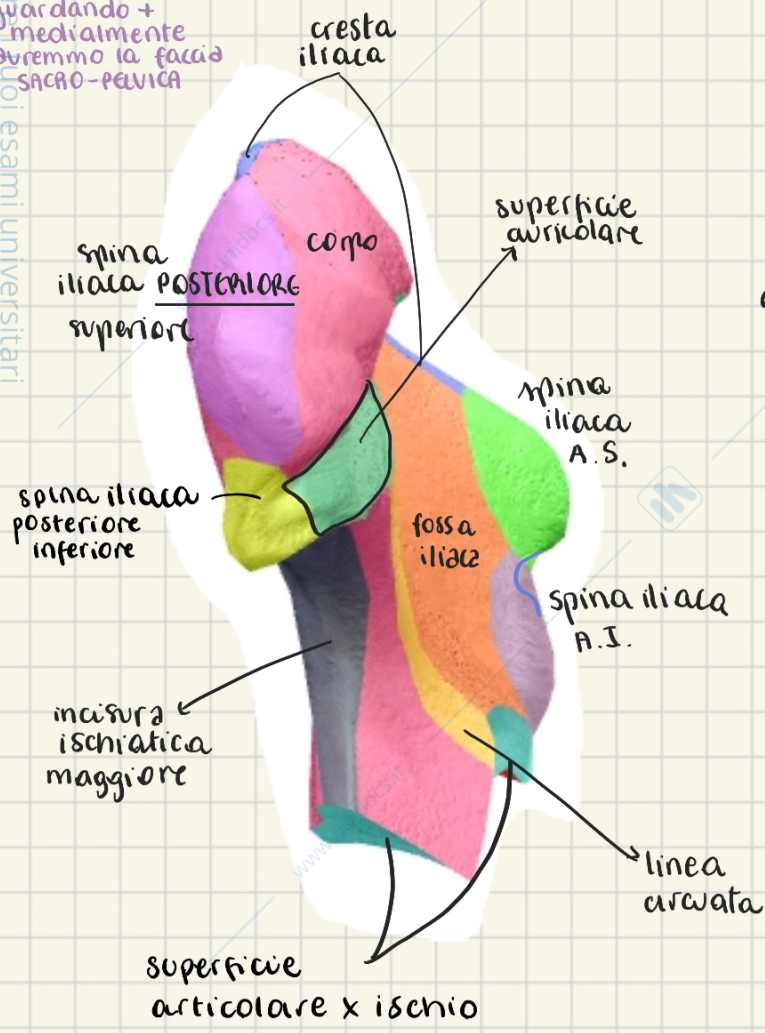


vista anteriore

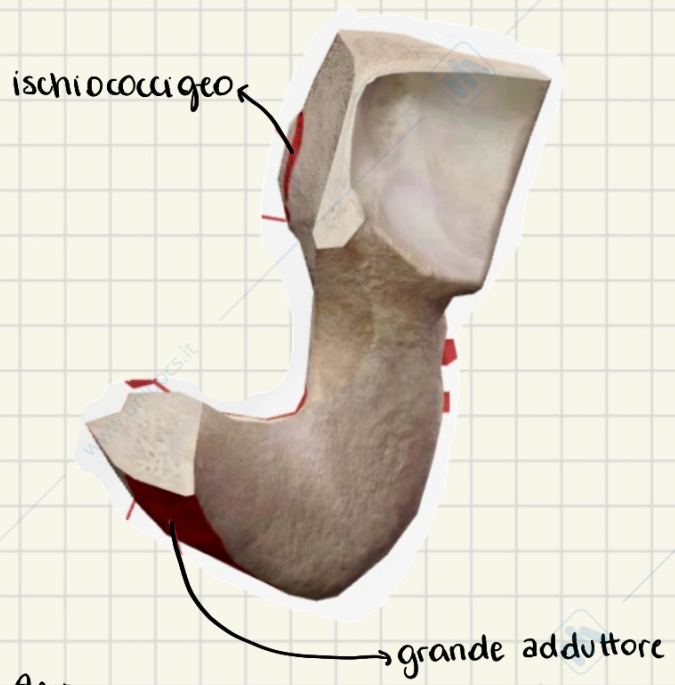
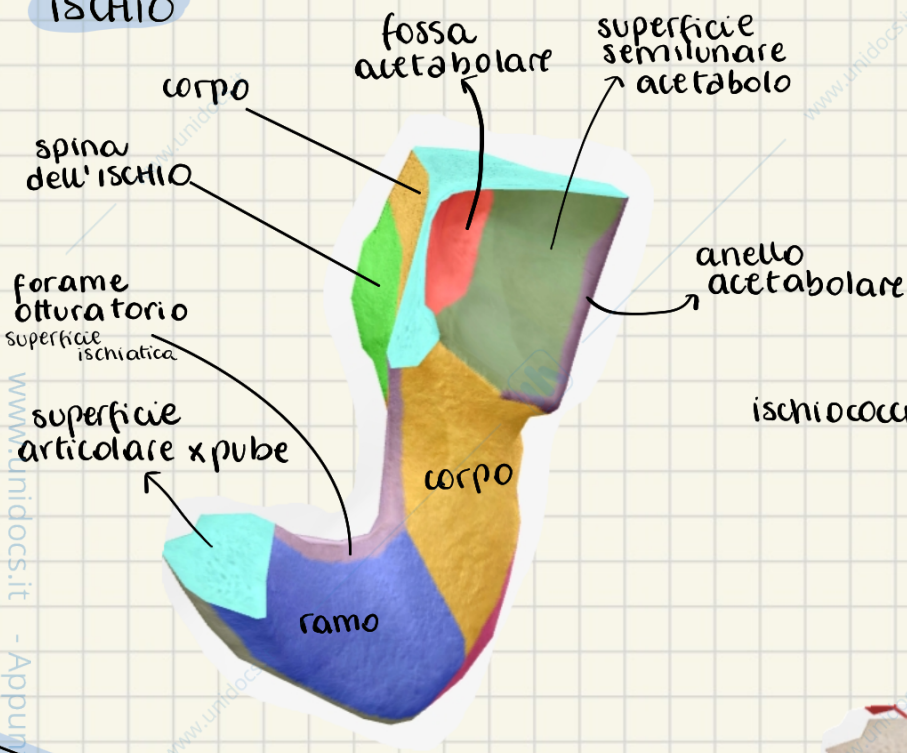


VISTA POSTERIORE

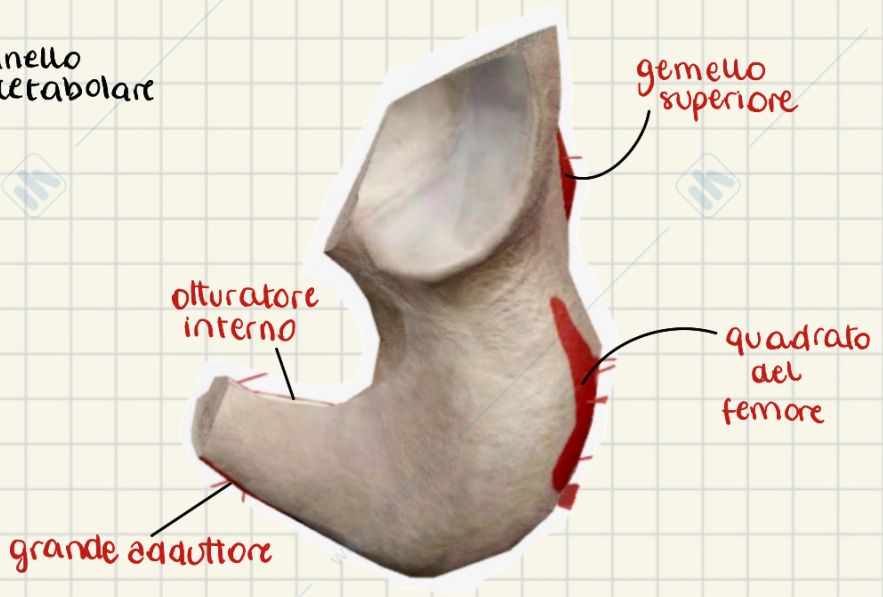
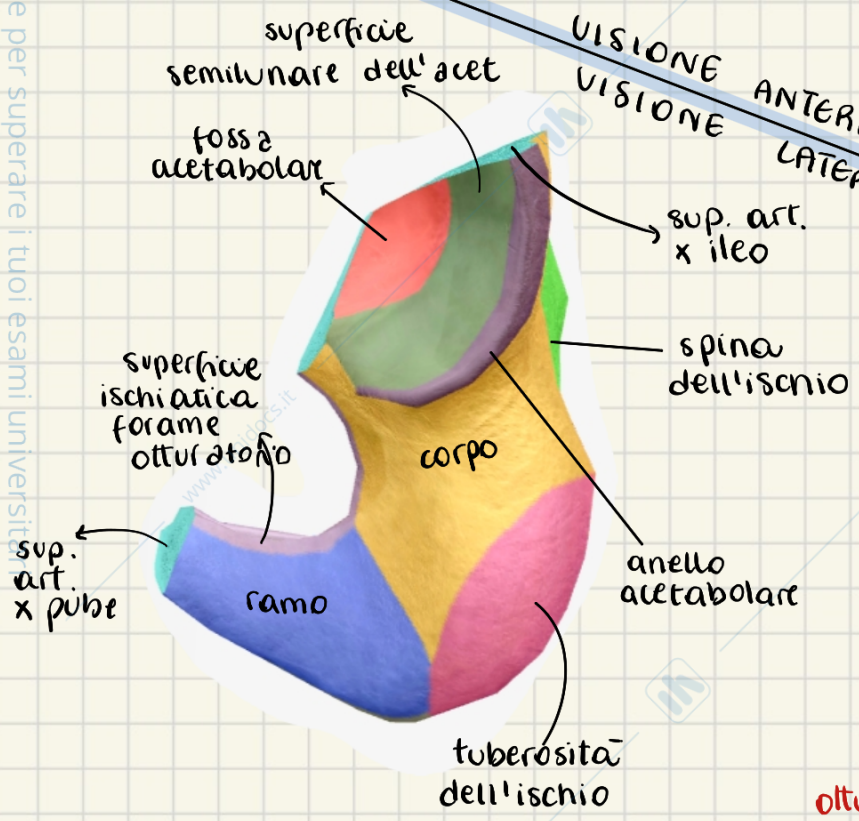
guardando + medialmente avremmo la faccia SACRO-PUBICA

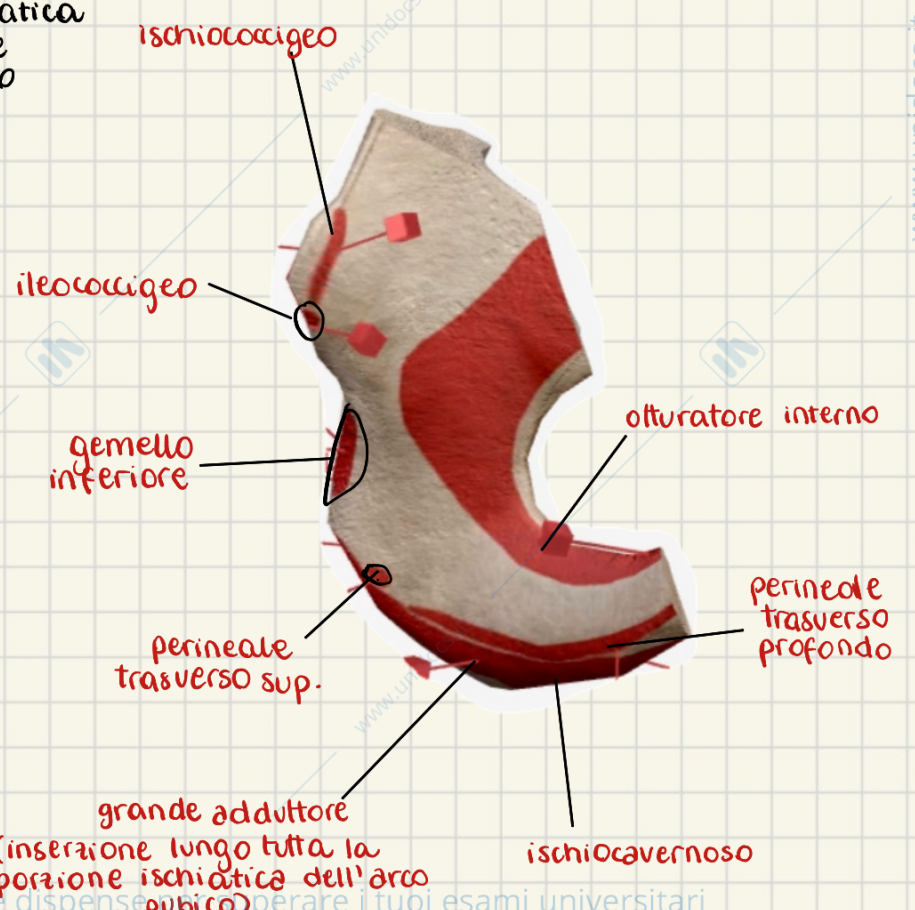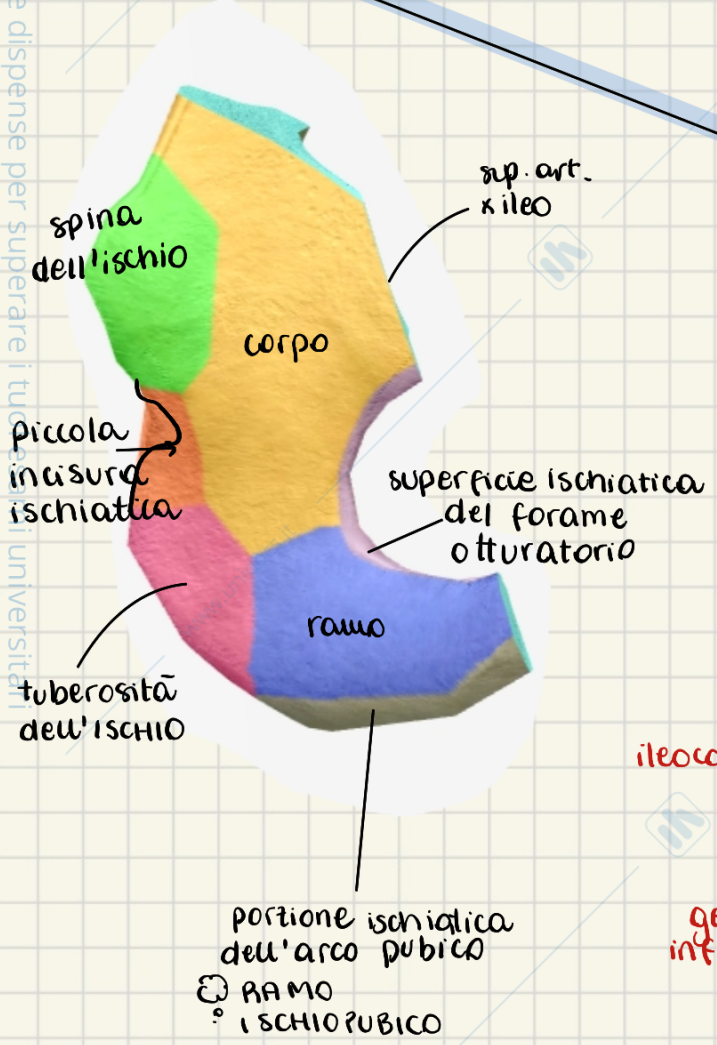
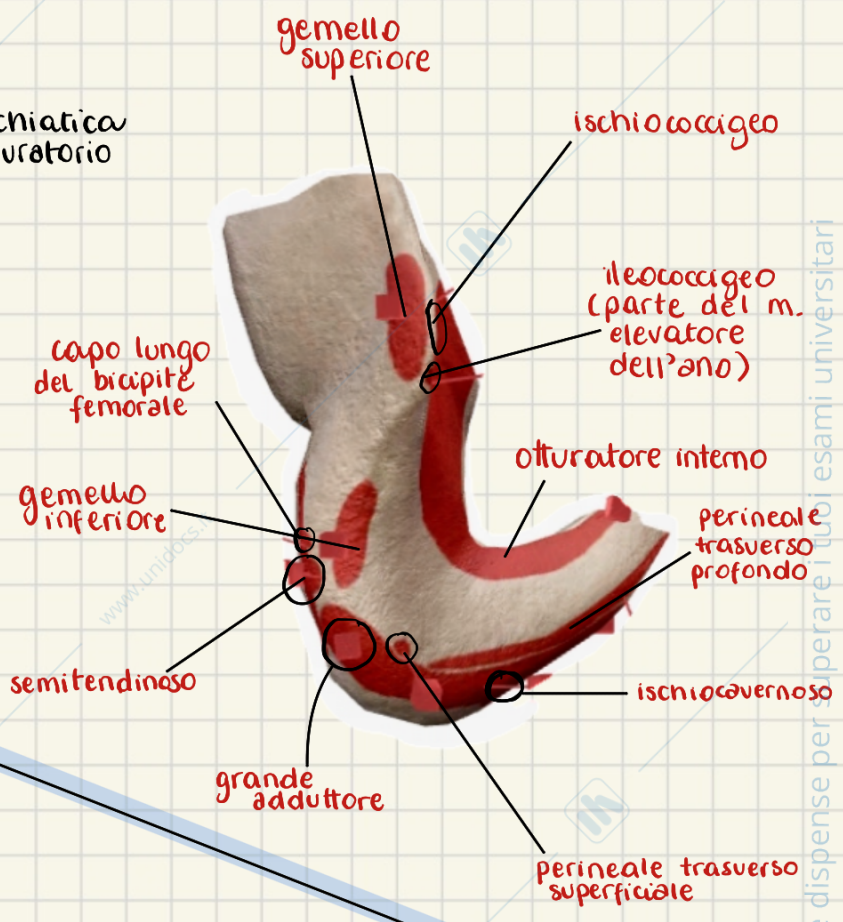
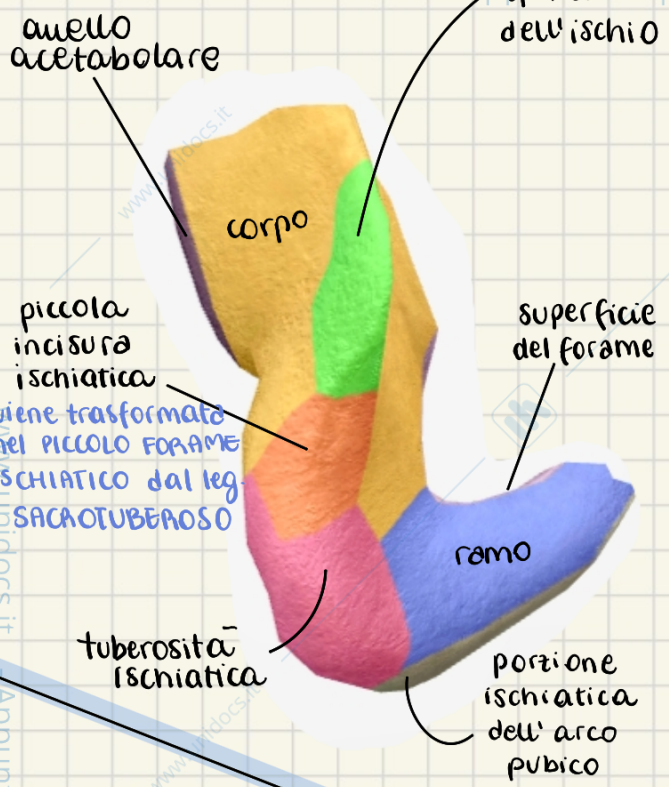


ISCHIO

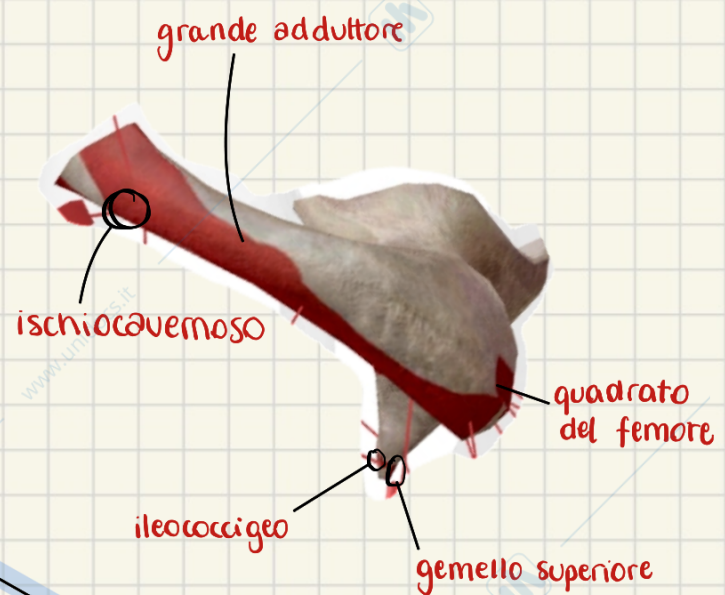
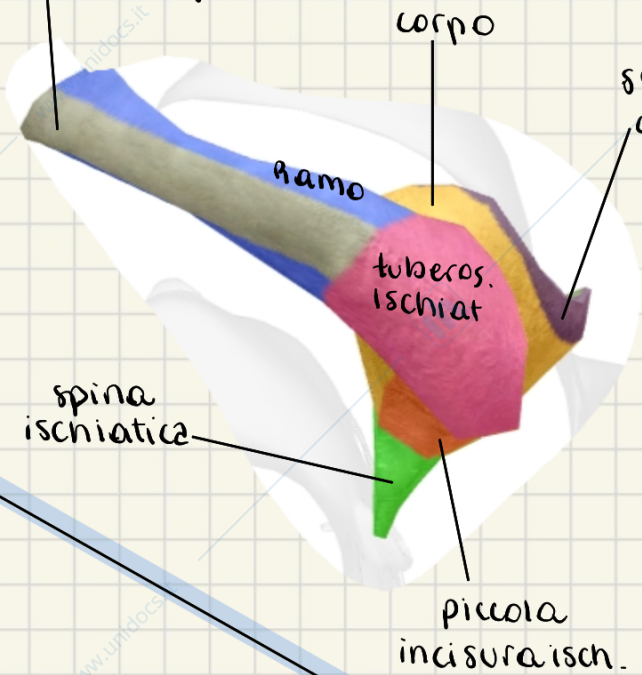


VISIONE ANTERIORE VISIONE LATERALE

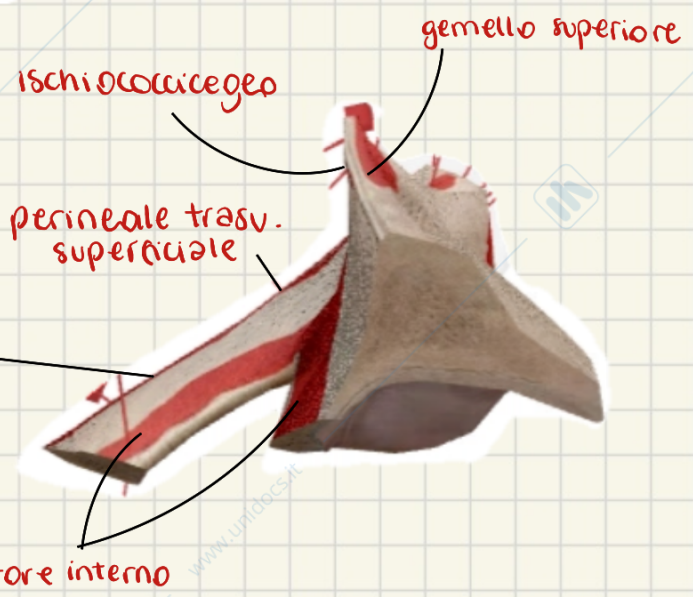
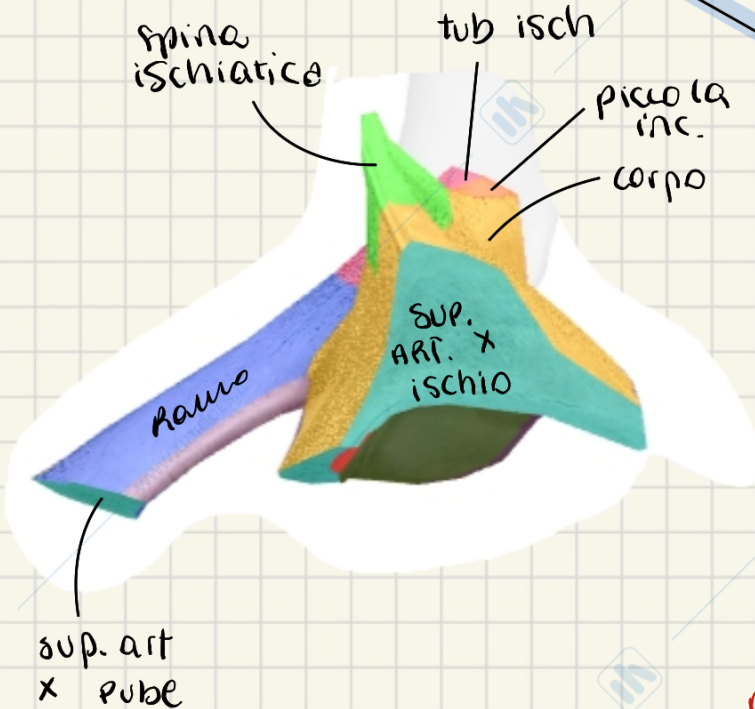




porzione isch.
dell' arco pubico



spina ischiatica
tub isch
piccola inc.
corpo



PUBE

cresta oturatoria o "linea pettinea"

- falce inguinale o tendine congiunto
- legamento lacunare
- legamento pettineo

cresta pubica

faccia sinfisaria è unita con la corrispondente contralaterale nella SINFISI PUBICA

ramo inferiore

sup. pubica
forame oturatorio

ramo superiore

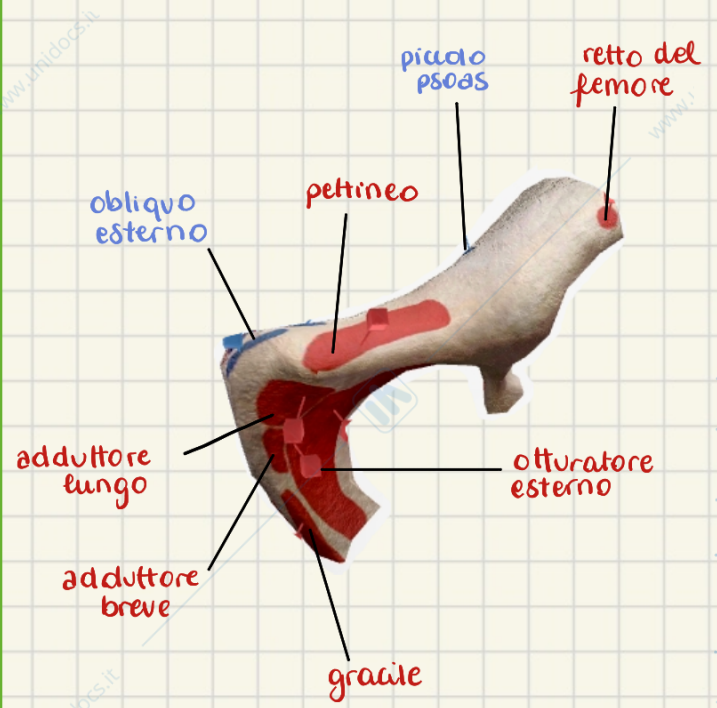
corpo

eminenza ileopubica

incisura acetabolare

tubercolo pubico:

- insr. pz. M del leg. inguinale
- parte pavim. anello ing. superf.
- nei M, nascosto da funicolo spermatico



insezione x molti muscoli della porzione mediale della coscia

FACCIA ANTERIORE

superficie articolare per:

- iliaco
- ischiatico
- pube opposto

eminenza ileopubica

ramo sup.

tubercolo pubico

cresta oturatoria

corpo

ramo inferiore

superficie semilunare dell'acetabolo

fossa acetabolare

incisura acetabolare

superficie pubica del forame oturatorio

FACCIA LATERALE

retto del femore

pettineo

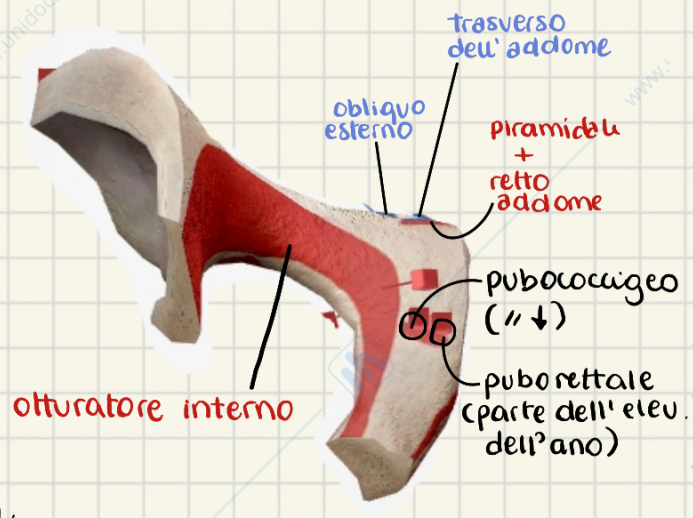
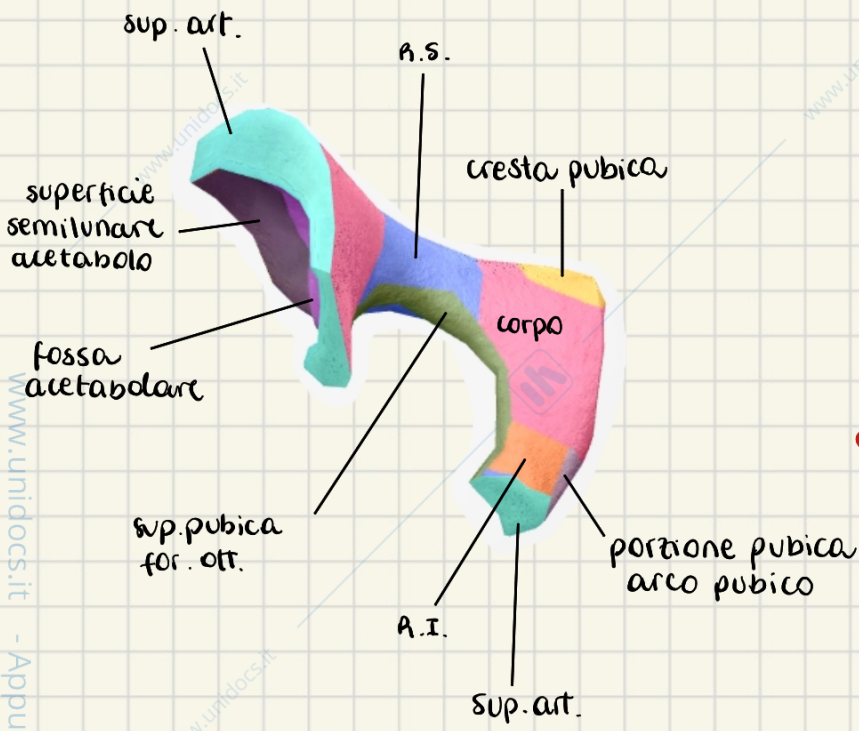
adduttore lungo

adduttore breve

gracile

otturatore interno

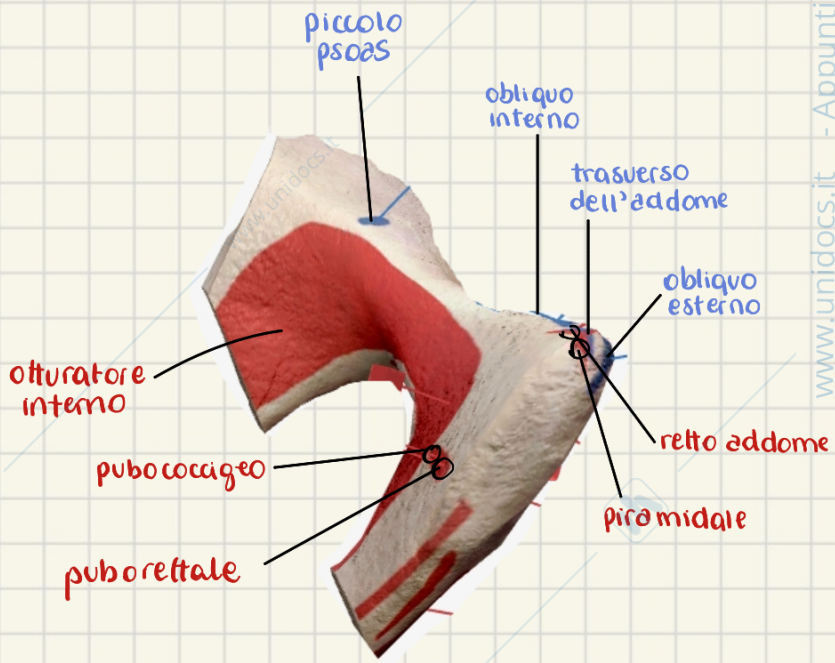
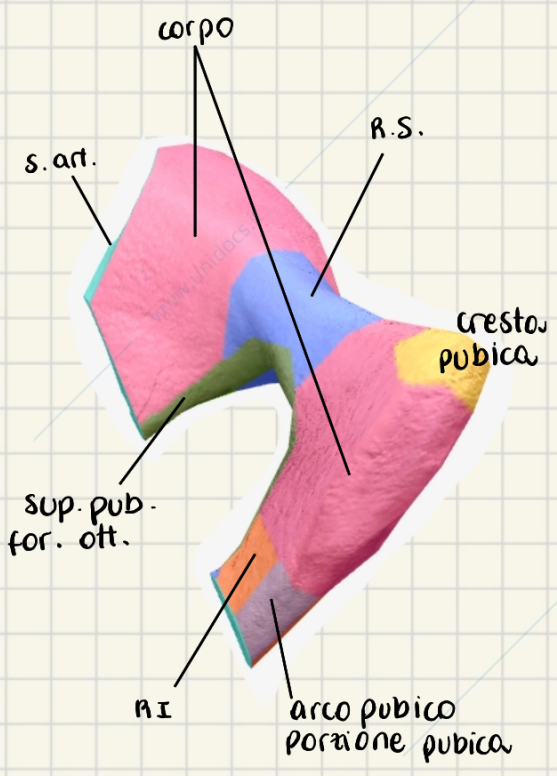
otturatore esterno

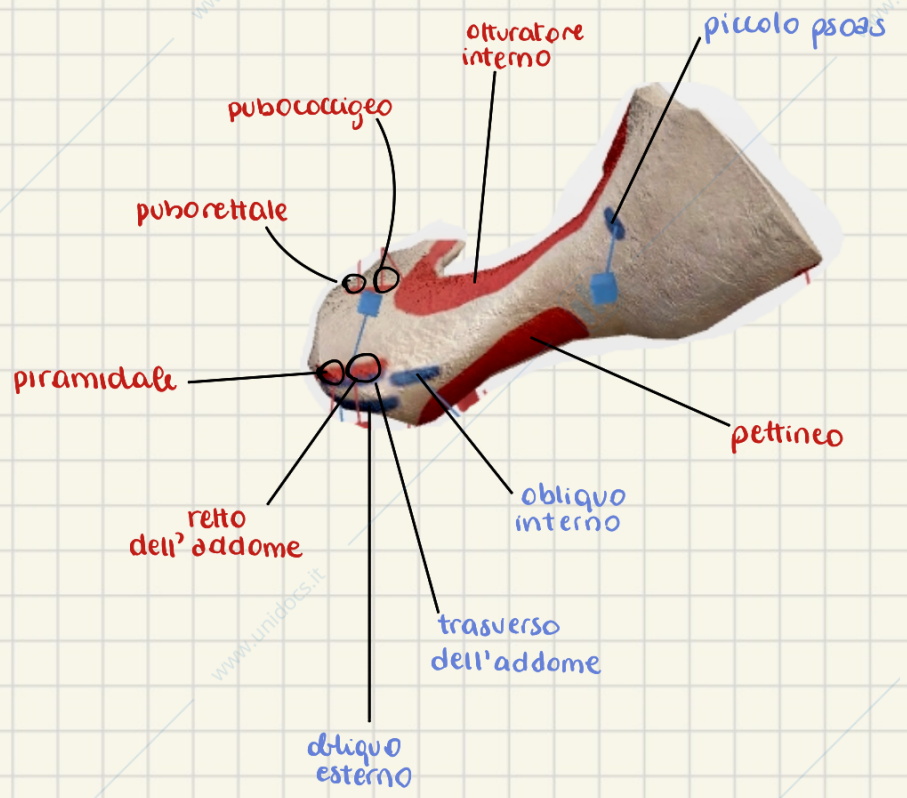
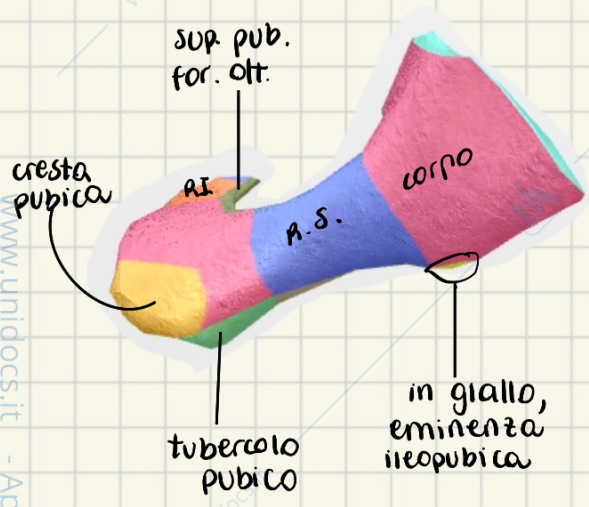


è in relazione con la vescica

FACCIA POSTERIORE

FACCIA MEDIALE





F. SUPERIORE

F. MEDIALE

